

IMMEDIATE LOADING USING A ONE-PIECE IMPLANT WITH INTEGRATED MUA AND COMPUTER-AIDED PLANNING

A. Scarano^{1†}, F. Tricca¹, P. Cozza¹, C. Bugea^{1†}, S.A. Gehrke^{3,4†} and S.R. Tari¹

¹Department of Innovative Technologies in Medicine and Dentistry, University of Chieti-Pescara, Chieti, Italy;

²Health Affairs Directorate, Egyptian Ministry of Health and Population, Banisuf Egypt;

³Department of Research, Bioface/PgO/UCAM, Montevideo, Uruguay;

⁴Department of Biotechnology. Universidad Católica de Murcia (UCAM), Murcia, Spain;

⁵Department of Interdisciplinary Medicine, Section of Dentistry, University of Bari School of Medicine, Bari, Italy

†These authors contributed equally to this work as co-first Authors

*Correspondence to:

Antonio Scarano, DDS, MD

Department of Innovative Technology in Medicine and Dentistry,

University of Chieti-Pescara,

Via Dei Vestini 31,

66100 Chieti Italy

e-mail: ascarano@unich.it

ABSTRACT

Computer-aided dental implant planning increases the success and predictability of replacing missing teeth in fully and partially edentulous cases. Immediate loading techniques have raised the issue of dealing with it even in severe bone atrophy, in which the situations are characterized by numerous technical difficulties. It is known that each implant immediately loaded must be protected from excessive micro-movements, which can be deleterious in the healing phase and negatively influence the reparative processes of bone remodeling in the first weeks. The purpose of this paper is to evaluate a protocol for immediate loading with a one-piece implant with integrated MUA and computer-aided planning. The study involved 20 patients with 160 implants that were immediately solidified with a provisional prosthesis without reinforcement, made immediately after the surgery. Each patient received eight Uniko implants per arch. All implants subjected to immediate loading have resulted in a success rate of 100% over the 36 months that have occurred without fracture of the provisional. This technique, supported by computer-assisted design, has allowed the implementation of immediate loading in full edentulous patients.

KEYWORDS: *computer-aided dental implant, one-piece implant, integrated MUA*

INTRODUCTION

The initial premise in implantology fervently maintained that the osseointegration process of a dental implant required three to six months to achieve complete bone healing in the absence of load and with a submerged technique (1-3). Over time, there has been increasing interest in transmucosal techniques and, subsequently, in the early or immediate

Received: 12 July 2022
Accepted: 18 August 2022

Copyright © by LAB srl 2022
This publication and/or article is for individual use only and may not be further reproduced without written permission from the copyright holder. Unauthorized reproduction may result in financial and other penalties. Disclosure: All authors report no conflicts of interest relevant to this article.

loading of implants (4, 5). The push towards immediate loading originates from the consideration that during the healing phase of implants in edentulous jaws, providing the patient with removable temporary prostheses is not without disadvantages, such as the need for frequent relining and reduced stability with the risk of implant load on non-stabilized implants.

The quality and precision of the interface between the fixture and abutment are undoubtedly strategic elements in remodeling the crestal bone, the success, and the maintenance of the health of peri-implant hard and soft tissues (6). Schwartz et al. described in great detail the events leading to bone formation around implants, highlighting that during the healing phases, the implant requires maximum stability relative to the bone (7). Being a dynamic entity, bone tissue modifies its characteristics in response to mechanical, bioelectric, and biohumoral stimuli (8, 9). It has been demonstrated that immediate loading does not impede osseointegration but can accelerate bone repair if implemented with appropriate techniques and rigorous clinical protocols (10).

The key is to counteract the loads that can produce micromovements at the interface between the implant and bone, which could interfere with the bone healing process and damage osteogenetic repair processes, preventing osseointegration and leading to the formation of fibrous tissue and encapsulation of the implant (11). According to Brunski et al., implants can be loaded early or immediately if micromovements do not exceed the threshold of 100-150 μm , emphasizing that movements beyond this limit must be neutralized during the healing phase (11). Degidi et al., in a clinical study involving and analyzing a significant number of implants, demonstrated the predictability and a high success rate of functional and non-functional immediate loading (12).

For many years, it was thought that the success of an immediately loaded implant rehabilitation depended on the large number of implants involved to distribute occlusal loads, limit the distance between pillars, and avoid the fracture of the temporary prosthesis. Subsequently, the criteria of careful pre-surgical diagnosis, a correct treatment plan, and the application of techniques capable of eliminating or reducing the possibility of micro-movements and the consequent risks to the surrounding bone prevailed. Protecting the bone-implant interface from micromovements is a strategic element of the success and survival of implants. In recent years, various techniques have been described to improve the predictability of immediate loading: bars as support for overdentures (13), the use of previous prostheses to achieve implant stability, or the use of acrylic temporaries by combining transition implants and standard ones (14-17).

Longoni et al. described a method to reduce prosthetic misfit with an implant-supported prosthesis using a technique that involved intraoral bonding with composite material and laser welding of the framework in the laboratory (18). In the early 80s, Mondani et al. (19) and Ar et al. (20) described a method to reduce the misfit or lack of adaptation of complete prostheses on implants, proposing an intraoral welding technique that avoided laborious laboratory procedures.

Szmukler-Moncler et al. described an intraoral welding technique to join implants using a preconstructed round titanium wire, followed by an immediate acrylic provisional application immediately post-surgery directly in the oral cavity (21). The present work aims to evaluate a protocol of immediate loading using a one-piece implant with integrated MUA and Computer-aided planning.

MATERIALS AND METHODS

Twenty patients with at least one completely edentulous arch (average age of 61.4 years) requiring prosthetic rehabilitation were selected. Exclusion criteria included severe systemic diseases, patients irradiated less than a year ago or undergoing chemotherapy, patients with severe periodontal disease, and heavy smokers. After a careful preliminary oral examination, the general health status and necessary information regarding the immediate loading technique procedure were assessed. In each case, the patient prepared and signed an informed consent form. The study was conducted in accordance with the ethical standards outlined in the 1964 Declaration of Helsinki.

A total of 160 Uniko implants (Isomed System, Due Carrare, Padova, Italy) of varying diameters were placed depending on clinical conditions. Each patient received eight Uniko implants. All 160 implants were splinted through resin prostheses without reinforcement and immediately loaded. None of the selected patients required additional techniques to increase bone volumes concurrently with implant insertion. Patients were prescribed appropriate pre- and post-surgical pharmacological therapy: amoxicillin (1 g twice a day for 5 days) and analgesics for 1 week (Ibuprofen 600 mg), as needed. Before surgery, all patients performed rinses with 0.2% chlorhexidine digluconate for 2 minutes. Local anesthesia was administered with Articaine® (Ubistesin 4% - Espe Dental AG Seefeld, Germany) combined with epinephrine 1:100,000.

The superimposition of STL and DICOM files allowed the virtual planning of one-piece implants in the ideal prosthetic implant position using the dedicated software Isoguide (Isomed System, Due Carrare, Padova, Italy). The

stackable guides, composed of a fixed base template and additional removable components, were then realized. The fixed template, initially secured with anchor pins to the bone, was no longer removed. The removable components, which were screwed to the base template, were used to perform implant surgery and immediate prosthetic loading.

A CBCT scan was performed to evaluate the bone height and thickness, and standard triangulation language (STL) files obtained from the digital scan were aligned with the digital imaging and communication in medicine (DICOM) data retrieved from the CBCT scan.

A Transmucosal Implant (Isomed System, Due Carrare, Padova, Italy) was placed as a natural extension through the gingival thickness using a surgical guide. The software is also able to assess the quality of bone tissue. The provisional restoration was delivered 6 hours after surgery or the next day, depending on the complexity of the cases, the duration of the surgeries, and the patient's psycho-physical condition. The completed fixed provisional prosthesis was placed in the patient's mouth and fixed with retention screws appropriate for each MUA. The screw access holes were then sealed by placing a Teflon followed by a light-curable temporary composite (Fermit®, Ivoclar Vivadent), finishing the closure, and polishing the provisional restoration to a mirror finish to reduce bacterial plaque formation and ensure satisfactory aesthetics.

Before discharging the patient, radiographic examinations with intraoral radiographs were performed using a parallel technique to evaluate the adaptation of the titanium structure to the transmucosal collars. After delivering the immediate prosthesis, the patient was followed up after 7 days and subsequently every 30 days.

RESULTS

No intraoperative complications, such as soft tissue lacerations, profuse bleeding, template fractures, or implant misplacement with consequent dehiscences or fenestrations, occurred during the procedure. All implants achieved a range insertion torque range of 35-50 Ncm, so immediate prosthetic loading could be performed safely. The presence of a one-piece implant with integrated MUA and Computer-aided planning and the provisional prosthesis has shown a significant impact on the health of peri-implant tissues in immediate loading, as it reduces mechanical stress on each implant and allows for excellent healing and quality of peri-implant tissues (Fig. 1-6).



Fig. 1. The morphology of a one-piece implant with integrated.... questa leggenda non è completa

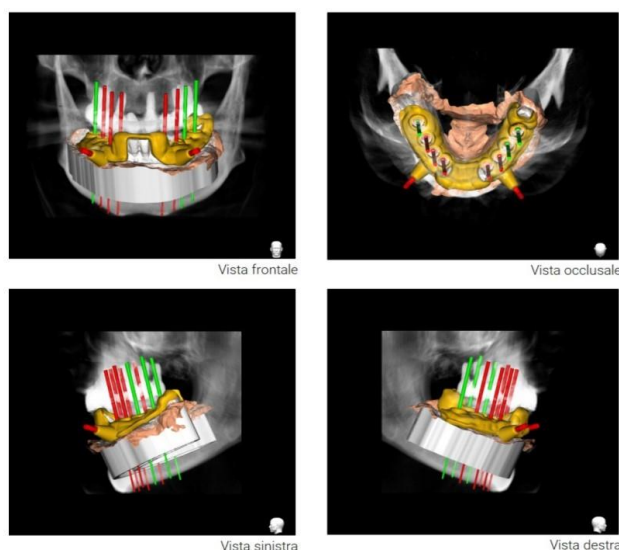


Fig. 2. Steps of guided computer planning.

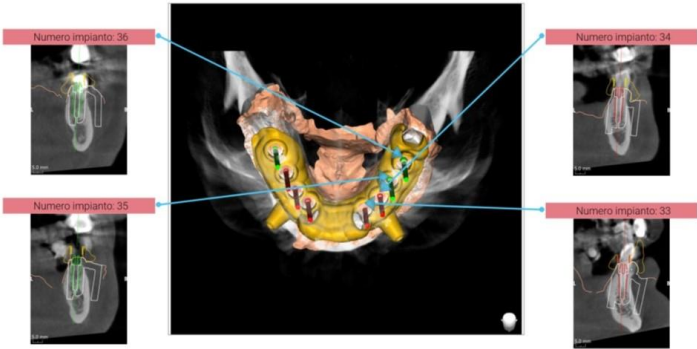


Fig. 3. Steps of guided computer planning with 3D visualisation of implant position.

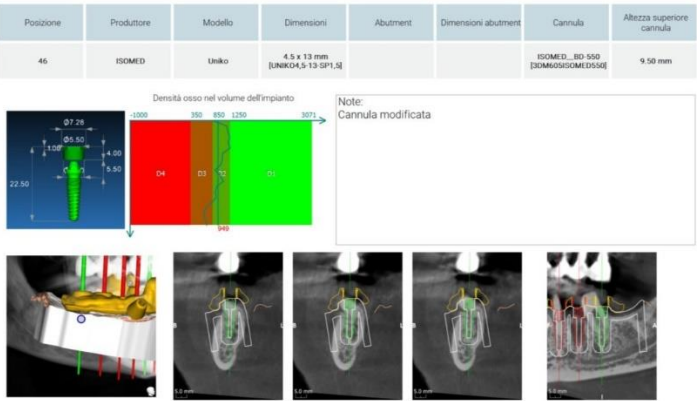


Fig. 4. Implant structure and visualization of bone quality.

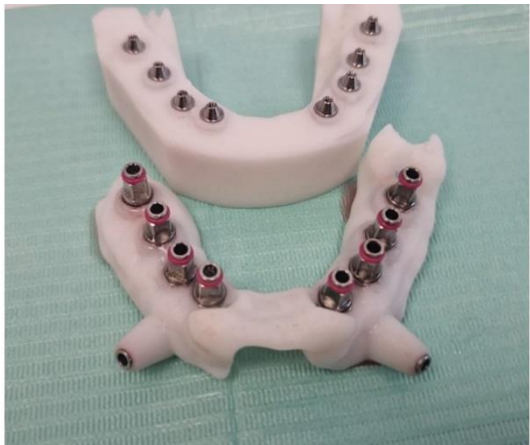

Fig. 5. Structure containing the implant and position of the prosthesis.

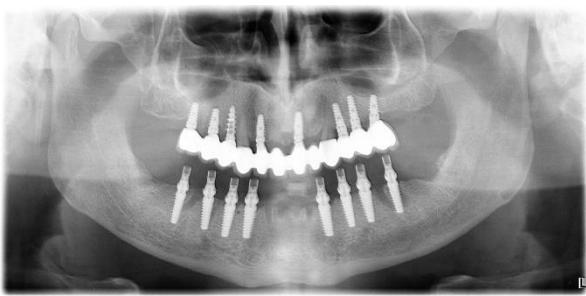


Fig. 6. Post operative x-ray demonstrating perfect prosthesis congruence on UNIKO implants.

All 160 implants in the study achieved a 100% success rate over 6 months. During the observation period, there were no fractures of the provisional prosthesis or loosening of the screw of the abutments, and radiographic checks were performed to evaluate the peri-implant bone levels.

DISCUSSION

A one-piece implant with integrated MUA and Computer-aided planning can increase the passivity of the prosthesis, which is crucial in the immediate loading rehabilitation of fully edentulous patients. Another advantage of integrated MUA is eliminating the micro gap between the implant and abutment, which is responsible for crestal bone resorption (22, 23). It is now established that micromovements exceeding 100-150 microns (11) lead to fibrous tissue formation, preventing implant osseointegration (21).

Various protocols have been described in recent years, but they have not proven effective in routinely achieving a passive structure while reducing chairside costs and time (18). Acrylic resin bridges with significant distances between the abutments tend to “warp” as they are subject to flexion and often fracture under occlusal forces; this is particularly true for the edentulous mandible, which presents a biomechanical elastic complex particularly sensitive to functional loads. This is due to the “U” shape of the mandible, the posterior insertion of the masticatory muscles, and the complex elastic structures that make up the bone (24). During the mandibular opening, the lateral pterygoid muscles exert a lateral protrusion, contract simultaneously, and exert downward traction on the condyles. Consequently, there is elastic flexion of the mandible, with the distance at the mandibular ramus level of both sides reducing on the frontal plane. Additionally, there is flexion at the mandibular symphysis, reducing the width of the posterior segment of the mandible (25).

In the past, it has been observed that the fragility of acrylic resin prosthetic restorations was able to redistribute occlusal loads physiologically only by introducing a greater number of implants to reduce mobility during the first weeks, where initial primary stability is lost before achieving secondary stability (25-27). Conversely, Degidi demonstrated the importance of rigid splinting in the mandible, indicating it as the most favorable condition for immediate loading, even with a reduced number of implants (28).

Creating a titanium splinting structure directly in the mouth highlights the advantages of immediate loading. It allows for verifying its real passive adaptation in the patient’s mouth. Moreover, it avoids delegating the structure’s fabrication to the laboratory, which would require subsequent in-mouth trials, increasing the cost and extending the wait time for verifying the structure’s adaptation to the implants and fabricating the provisional prosthesis. Degidi and colleagues demonstrated the utility of intraoral welding using synchro-welding to achieve rigid splinting of implants subjected to immediate loading (28). The solution described in this work helps counteract jaw flexions so that they do not impact the provisional prostheses, causing fractures and destabilizing the ongoing osteogenic process.

This technique consists of a one-piece implant with integrated MUA, which distributes the occlusal loads over multiple implants. With reduced costs, this protocol enables the fabrication of immediate-load prostheses in the short term, gaining greater patient acceptance. Further investigations on a larger sample of clinical cases will validate the procedure described here as a routine and predictable solution for immediate loading through stabilizing the provisional prosthesis.

CONCLUSIONS

In the cases examined, no provisional fractures occurred. The one-piece implant with integrated MUA supported (Uniko) by careful computer-assisted planning has demonstrated clinical efficacy and reliability. It also enabled the implementation of sufficiently predictable immediate loading protocols, even in challenging cases.

Conflicts of interest

The authors declare that they have no conflicts of interest.

REFERENCES

1. Brånemark PI, Hansson BO, Adell R, et al. Osseointegrated implants in the treatment of the edentulous jaw. Experience from a 10-year period. *Scandinavian Journal of Plastic and Reconstructive Surgery Supplementum*. 1977;16:1-132.
2. Adell R, Lekholm U, Rockler B, Brånemark PI. A 15-year study of osseointegrated implants in the treatment of the edentulous jaw. *International Journal of Oral Surgery*. 1981;10(6):387-416. doi:[https://doi.org/10.1016/s0300-9785\(81\)80077-4](https://doi.org/10.1016/s0300-9785(81)80077-4)
3. Albrektsson T, Dahl E, Enbom L, et al. Osseointegrated Oral Implants. *Journal of Periodontology*. 1988;59(5):287-296. doi:<https://doi.org/10.1902/jop.1988.59.5.287>
4. Buser D, Belser UC, Lang NP. The original one-stage dental implant system and its clinical application. *Periodontology* 2000. 1998;17(1):106-118. doi:<https://doi.org/10.1111/j.1600-0757.1998.tb00128.x>
5. Szmukler-Moncler S, Piattelli A, Favero GA, Dubruille JH. Considerations preliminary to the application of early and

- immediate loading protocols in dental implantology. *Clinical Oral Implants Research*. 2000;11(1):12-25. doi:https://doi.org/10.1034/j.1600-0501.2000.011001012.x
6. Assenza B, Scarano A, Petrone G, et al. Crestal Bone Remodeling in Loaded and Unloaded Implants and the Microgap: A Histologic Study. *Implant Dentistry*. 2003;12(3):235-241. doi:https://doi.org/10.1097/01.id.0000074081.17978.7e
 7. Schwartz Z, Boyan BD. Underlying mechanisms at the bone-biomaterial interface. *Journal of Cellular Biochemistry*. 1994;56(3):340-347. doi:https://doi.org/10.1002/jcb.240560310
 8. Berglundh T, Lindhe J, Jonsson K, Ericsson I. The topography of the vascular systems in the periodontal and peri-implant tissues in the dog. *Journal of Clinical Periodontology*. 1994;21(3):189-193. doi:https://doi.org/10.1111/j.1600-051x.1994.tb00302.x
 9. Davies JE. Understanding Peri-Implant Endosseous Healing. *Journal of Dental Education*. 2003;67(8):932-949. doi:https://doi.org/10.1002/j.0022-0337.2003.67.8.tb03681.x
 10. A. Piattelli, Corigliano M, Scarano A, G. Costigliola, Paolantonio M. Immediate Loading of Titanium Plasma-Sprayed Implants: An Histologic Analysis in Monkeys. *J Periodontol*. 1998;69(3). doi:https://doi.org/10.1902/jop.1998.69.3.321
 11. Brunski JB. Biomechanical factors affecting the bone-dental implant interface. *Clinical Materials*. 1992;10(3):153-201. doi:https://doi.org/10.1016/0267-6605(92)90049-y
 12. Degidi M, Adriano Piattelli. Comparative analysis study of 702 dental implants subjected to immediate functional loading and immediate nonfunctional loading to traditional healing periods with a follow-up of up to 24 months. *Int J Oral Maxillofac Implants*. 2005;20(1):99-107.
 13. Chiapasco M, Gatti C, Rossi E, Haefflge W, Markwaldel. TH. Implant-retained mandibular overdentures with immediate loading. *Clinical Oral Implants Research*. 1997;8(1):48-57. doi:https://doi.org/10.1111/j.1600-0501.1997.tb00007.x
 14. Balshi TJ, Wolfinger GJ. Conversion prosthesis: a transitional fixed implant-supported prosthesis for an edentulous arch--a technical note. *Int J Oral Maxillofac Implants*. 1996;11(1):106-111.
 15. Jaffin RA, Kumar A, Berman CL. Immediate Loading of Implants in Partially and Fully Edentulous Jaws: A Series of 27 Case Reports. *Journal of Periodontology*. 2000;71(5):833-838. doi:https://doi.org/10.1902/jop.2000.71.5.833
 16. Rodrigues AHC, Morgano SM, Guimarães MM, Ankly R. Laboratory-processed acrylic resin provisional restoration with cast metal substructure for immediately loaded implants. *The Journal of Prosthetic Dentistry*. 2003;90(6):600-604. doi:https://doi.org/10.1016/j.prosdent.2003.08.006
 17. Froum S, Emtiaz S, Bloom Mj, Scolnick J, Tarnow Dp. The use of transitional implants for immediate fixed temporary prostheses in cases of implant restorations. *Pract Periodontics Aesthet Dent*. 1998;10(6):737-746; quiz 748.
 18. Longoni S, Sartori M, Davide R. A simplified method to reduce prosthetic misfit for a screw-retained, implant-supported complete denture using a luting technique and laser welding. *The Journal of Prosthetic Dentistry*. 2004;91(6):595-598. doi:https://doi.org/10.1016/j.prosdent.2004.02.016
 19. Mondani PL, Mondani PM. [The Pierluigi Mondani intraoral electric solder. Principles of development and explanation of the solder using syncrystallization]. *Rivista di odontostomatologia e implantoprotesi*. 2018;4(4).
 20. Ar H, Borelli P. Intra-oral welding of implants for an immediate load with overdentures. *J Oral Implantol*. 1993;19(1):34-38.
 21. Szmukler-Moncler S, Salama H, Reingewirtz Y, Dubruille JH. Timing of loading and effect of micromotion on bone-dental implant interface: review of experimental literature. *Journal of biomedical materials research*. 2014;43(2). doi:https://doi.org/10.1002/(sici)1097-4636(199822)43:2%3C192::aid-jbm14%3E3.0.co;2-k
 22. Mihali S, Wang HL, Karancsi O, Bratu EA. Internal hexagon versus conical implant-abutment connections: evaluation of 3-year postloading outcomes. *Journal of Oral Implantology*. 2020;47(6). doi:https://doi.org/10.1563/aaid-joi-d-19-00160
 23. Scarano A, Valbonetti L, Degidi M, et al. Implant-Abutment Contact Surfaces and Microgap Measurements of Different Implant Connections Under 3-Dimensional X-Ray Microtomography. *Implant Dentistry*. 2016;25(5):656-662. doi:https://doi.org/10.1097/id.0000000000000465
 24. Zarone F, Apicella A, Nicolais L, Aversa R, Sorrentino R. Mandibular flexure and stress build-up in mandibular full-arch fixed prostheses supported by osseointegrated implants. *Clinical Oral Implants Research*. 2003;14(1):103-114. doi:https://doi.org/10.1034/j.1600-0501.2003.140114.x
 25. Hobkirk JA, Schwab J. Mandibular deformation in subjects with osseointegrated implants. *Int J Oral Maxillofac Implants*. 1991;6(3):319-328.
 26. Becker W, Becker BE, Huffstetler S. Early Functional Loading at 5 Days for Brånemark Implants Placed into Edentulous Mandibles: A Prospective, Open-Ended, Longitudinal Study. *Journal of Periodontology*. 2003;74(5):695-702. doi:https://doi.org/10.1902/jop.2003.74.5.695
 27. Balshi TJ; Wolfinger GJ. Conversion prosthesis: a transitional fixed implant-supported prosthesis for an edentulous arch--a technical note. *The International journal of oral & maxillofacial implants*. 2021;11(1).
 28. Degidi M, Gehrke P, Spanel A, Piattelli A. Syncrystallization: A Technique for Temporization of Immediately Loaded Implants with Metal-Reinforced Acrylic Resin Restorations. *Clinical Implant Dentistry and Related Research*. 2006;8(3):123-134. doi:https://doi.org/10.1111/j.1708-8208.2006.00011.x